

## Evaluation of Surgical Management in Condylar Hyperplasia: From Diagnosis to Treatment Monitoring \*

Evaluación del manejo quirúrgico en hiperplasia condilar: desde el diagnóstico hasta la monitorización del tratamiento

Avaliação do manejo cirúrgico em hiperplasia condilar: desde o diagnóstico até o monitoramento do tratamento

Eilien Gisek Tovío-Martínez <sup>a</sup>  
Institución Universitaria Visión de las Américas. Medellín, Colombia  
eilien.tovio@uam.edu.co  
<https://orcid.org/0000-0003-3702-2791>

DOI : <https://doi.org/10.11144/Javeriana.uo42.esmc>  
Submission Date: 23 May 2023  
Acceptance Date: 12 December 2023  
Publication Date: 30 December 2023

Samuel Enrique Urbano-del-Valle <sup>a</sup>  
Universidad de Antioquia. Medellín, Colombia.  
samuel.urbano@unicartagena.edu.co  
<https://orcid.org/0000-0002-5773-8642>

Leidy Laura Giraldo-Rendón <sup>a</sup>  
Institución Universitaria Visión de las Américas. Medellín, Colombia.  
leidy.giraldor@uam.edu.co  
<https://orcid.org/0009-0006-3122-1932>

Jarlinson Córdoba-Mosquera <sup>a</sup>  
Institución Universitaria Visión de las Américas. Medellín, Colombia  
jarlinson.cordoba@uam.edu.co  
<https://orcid.org/0009-0006-7423-686x>

**Authors' Note:** <sup>a</sup> **Correspondence:** eilien.tovio@uam.edu.co; samuel.urbano@unicartagena.edu.co; leidy.giraldor@uam.edu.co; jarlinson.cordoba@uam.edu.co

### ABSTRACT

**Background:** Condylar hyperplasia is an abnormal growth affecting the temporomandibular joint caused by overactive cells in mandibular condyle. It is relatively rare, and its exact frequency is unknown. **Purpose:** To describe the clinical, radiographic, and histological characteristics from pathology of two patients with active condylar hyperplasia, whose purpose is to focus on specific surgical treatment of condylar hyperplasia without the need for additional management with orthognathic surgery and its satisfactory evolution. **Methods:** A systematic review of the literature was carried out through of search in different databases such as LiLACS, PubMed, ScienceDirect and Scopus considering articles published between 2008 and 2023, a period of 15 years. 41 articles corresponding to literature reviews, clinical cases and systematic reviews were selected. **Results:** surgical management of condylectomy versus combined with orthognathic surgery, it was found that 63,64 % about the articles analyzed were treated only with high condylectomy and subsequent orthodontia, while 36,36 % of these were managed with high condylectomy plus orthognathic surgery in the same surgical act or in a second surgical procedure. **Presentation of cases:** The presentation of two clinical cases of condylar hyperplasia who report aesthetic and functional changes, treated with condylectomy on the affected side is made. **Conclusions:** Condylar hyperplasia is a pathological disorder characterized by generating asymmetries and facial deformations, deviations, malocclusions,

functional, aesthetic and psychological alterations, condylectomy being the procedure of choice which can be complemented with orthognathic surgery and orthodontics.

**Keywords:** condylar hyperplasia; dentistry; diagnosis; facial asymmetry; hyperplasia; maxillofacial surgery; oral surgery; malocclusion; mandibular condyle; oral medicine; oral pathology; panoramic radiograph

## RESUMEN

**Antecedentes:** La hiperplasia condilar es un crecimiento anormal que afecta la articulación temporomandibular causado por células hiperactivas en el cóndilo mandibular. Es relativamente raro y se desconoce la frecuencia exacta de ésta. **Objetivo:** Describir las características clínicas, radiográficas, e histológicas de la patología de dos pacientes con hiperplasia condilar activa, cuyo fin es enfocarse en el tratamiento quirúrgico específico de la hiperplasia condilar sin necesidad de manejo adicional con cirugía ortognática y su evolución satisfactoria. **Métodos:** Se llevó a cabo una revisión sistemática de la literatura a través de la búsqueda en diferentes bases de datos como LiLACS, PubMed, ScienceDirect y Scopus se consideran artículos publicados entre 2008 y 2023, lapso de 15 años. Fueron seleccionados 41 artículos correspondientes a revisiones de literatura, casos clínicos y revisiones sistemáticas. **Resultados:** el manejo quirúrgico de condilectomía versus combinado con cirugía ortognática se encontró que en el 63,64 % de los artículos analizados se trataron únicamente con condilectomía alta y posterior ortodoncia, mientras que el 36,36 % de éstos se manejaron con condilectomía alta más cirugía ortognática en el mismo acto quirúrgico o en un segundo tiempo quirúrgico. **Presentación de casos:** Se realiza la presentación de dos casos clínicos de hiperplasia condilar quienes refieren cambios estéticos y funcionales, tratados con condilectomía del lado afectado. **Conclusiones:** La hiperplasia condilar es un trastorno patológico caracterizado por generar asimetrías y deformaciones faciales, desviaciones, maloclusiones, alteraciones funcionales, estéticas y psicológicas, siendo la condilectomía el procedimiento de elección, pudiendo complementarse con cirugía ortognática y ortodoncia.

**Palabras clave:** asimetría facial; cirugía maxilofacial; cirugía oral; cóndilo mandibular; diagnóstico; hiperplasia; hiperplasia condilar; maloclusión; medicina oral; odontología; patología oral; radiografía panorámica

## RESUMO

**Antecedentes:** A hiperplasia condilar é um crescimento anormal que afeta a articulação temporomandibular causada por células hiperativas no côndilo mandibular. É relativamente raro e sua frequência exata é desconhecida. **Objetivo:** Descrever as características clínicas, radiográficas e histológicas da patologia de dois pacientes com hiperplasia condilar ativa, cujo objetivo é focar no tratamento cirúrgico específico da hiperplasia condilar sem a necessidade de manejo adicional com cirurgia ortognática e sua evolução satisfatória. **Métodos:** Foi realizada uma revisão sistemática da literatura por meio da busca em diferentes bases de dados como LiLACS, PubMed, ScienceDirect e Scopus considerando artigos publicados entre 2008 e 2023, um período de 15 anos. Foram selecionados 41 artigos correspondentes a revisões de literatura, casos clínicos e revisões sistemáticas. **Resultados:** manejo cirúrgico da condilectomia versus combinado com cirurgia ortognática, constatou-se que 63,64 % dos artigos analisados foram tratados apenas com condilectomia alta e posterior ortodontia, enquanto 36,36 % destes foram tratados com condilectomia alta mais cirurgia ortognática no mesmo ato cirúrgico ou em um segundo procedimento cirúrgico. **Apresentação dos casos:** É feita a apresentação de dois casos clínicos de hiperplasia condilar que relatam alterações estéticas e funcionais, tratadas com condilectomia no lado acometido. **Conclusões:** A hiperplasia condilar é um distúrbio patológico caracterizado por gerar assimetrias e deformações faciais, desvios, má oclusão, alterações funcionais, estéticas e psicológicas, a condilectomia é o procedimento de eleição e pode ser complementada por cirurgia ortognática e ortodontia.

**Palavras-chave:** assimetria facial; cirurgia maxilofacial; cirurgia oral; côndilo mandibular; diagnóstico; hiperplasia; hiperplasia condilar; má oclusão; medicina oral; odontologia; patologia oral; radiografia panorâmica

## INTRODUCTION

Condylar hyperplasia (CH) is a pathological disorder characterized by excessive and progressive growth of the mandibular condyle, body, neck or ramus. It can generate facial asymmetries and deformations, deviations, malocclusions, functional, aesthetic and psychological alterations which sometimes trigger painful symptoms. It is distinguished by having periods of activity, it affects people between the ages of 11 and 25 with a predilection for the female sex unilaterally due to the accumulation of estrogen, and sequelae can be observed throughout the life course (1,2).

Various theories have been reported to describe the etiopathogenesis of the disease, among which are: inflammation, trauma, hypervascularization, excessive unilateral chewing load, hormones, heredity

and osteoarthritis. These factors can generate limitations in mandibular movement, which generates occlusal interference when opening and closing the mouth, which causes alterations in the basic functions of the chewing apparatus (2,3).

The cartilage of the condyle appears in the ninth or tenth week of intrauterine life surrounded by mesenchymal tissue composed of various cells such as fibroblasts, osteoblasts and chondroblasts. First, there is a change in the differentiation of the chondroblasts where there is formation of the cartilage matrix, then there is maturation and hypertrophy of the chondrocytes, neovascularization, elimination of the matrix and osteogenesis. The condylar cartilage has special characteristics and is sensitive to external biomechanical, hormonal and growth stimuli. It is essential in the growth and size of the jaw since it has proprioceptors (4).

HC is among the most common causes of facial asymmetry. It was first described by Adams in 1836. According to Barajas *et al.* (5), the most accurate classification for this condition is one in which growth and amplitude are affected. of mandibular dimensions. In type I, unilateral or bilateral condylar and mandibular elongation is observed; Type II presents alteration in the condyle with lengthening, this in turn is subdivided into two types, type IIA presents a vertical growth vector with lengthening of the neck and condylar head, type IIB is usually caused by an osteochondroma in which a tumor elongation with outward growth in a horizontal direction; type III where benign tumors are found and Type IV where malignant tumors are found (5).

Other classifications of HC have been described in the literature, one of them is hemi mandibular hyperplasia, which presents an enlargement of the affected side of the face in all its dimensions. It can be found as a vertical, horizontal or hybrid dimension asymmetry, in most cases. cases appear at an early age (6).

HC presents a cartilaginous cover that covers the condylar surface which is divided into 4 layers: fibrous layer, layer of undifferentiated mesenchyme, cartilaginous layer with pre-hypertrophic and hypertrophic chondrocytes and the calcified cartilaginous layer. It has characteristics of endochondral ossification, the cartilage that covers the condyle is widened and the bone trabeculae are surrounded by newly formed osteoblasts (7).

The clinical diagnosis of condylar hyperplasia is made through radiographic examinations: panoramic, lateral cephalic, posteroanterior, computed tomography and bone scintigraphy in which an alteration in the shape and size of the condyle, ramus and mandibular body is seen, with deviation of the chin. and vertical excess of the alveolar processes of the mandible. Bone scintigraphy shows the cellular metabolic activity of osteoblasts and thus determines if the hyperplasia is active. If a difference in activity of more than 10 % is observed, it will give a diagnosis suggestive of HC. Regarding the SPECT-type tomographic examination, single-photon emission computed tomography obtains better sensitivity in identifying condylar hyperactivity (8).

The treatment will depend on the state of activity of the hyperplasia. When it is active, the clinician can decide whether to wait until the growth stops or whether to proceed with orthognathic surgery with or without pre-surgical orthodontics in combination with condylectomy, on the contrary, performing condylectomy individually is a technique used to a lesser extent today due to the aesthetic results obtained in consideration by the patient and the need for second interventions. Facial asymmetry is common in these patients, representing around 35 % of consultations in the area of orthognathic surgery, which is performed in severe class II and III cases, vertical discrepancies in patients who are not growing or as a complement to aesthetics and functionality (9-11).

The surgery-first approach is used thanks to the rapid acceleration phenomenon, which consists of activation of the healing process stimulated by ostectomy, which makes orthodontic treatments faster and more effective, promoting better facial harmony and patient self-esteem, demonstrating results similar to a conventional surgery. This technique is contraindicated in cases of lack of molar engagement, severe crowding, among others (12).

Due to all of the above, the question arises as to what clinical, radiographic and histological evidence supports specific surgical treatment for active condylar hyperplasia that allows a satisfactory evolution without requiring additional orthognathic surgery interventions, so the objective of this article is To evaluate the clinical, radiographic and histological characteristics of the pathology of patients who present active condylar hyperplasia, in order to focus on the specific surgical treatment of condylar hyperplasia without the need for additional management with orthognathic surgery and its satisfactory evolution, a Systematic review of the literature.

## MATERIALS AND METHODS

A systematic review of the literature was conducted through a search in different databases such as LiLACS, PubMed, ScienceDirect and Scopus. Articles published between 2008 and 2023, a period of 15 years, were considered to be found in indexed journals, systematic reviews. and case reports with simple or combined surgical management, with the objective of obtaining quality in the selection of documents, the parameters of relevance, originality, validity and contribution to the area to be investigated were used. “Condylar hyperplasia” “Unilateral condylar hyperplasia” and their equivalents in English were used as keywords; on the other hand, the Boolean connector AND was used as a connecting element. In the search with the term “Condylar hyperplasia” a total of 1,784 articles were obtained, of which 25 were selected. The search with the word “Condylar hyperplasia” AND “Unilateral” returned 923 articles of which 16 were selected (figure 1).

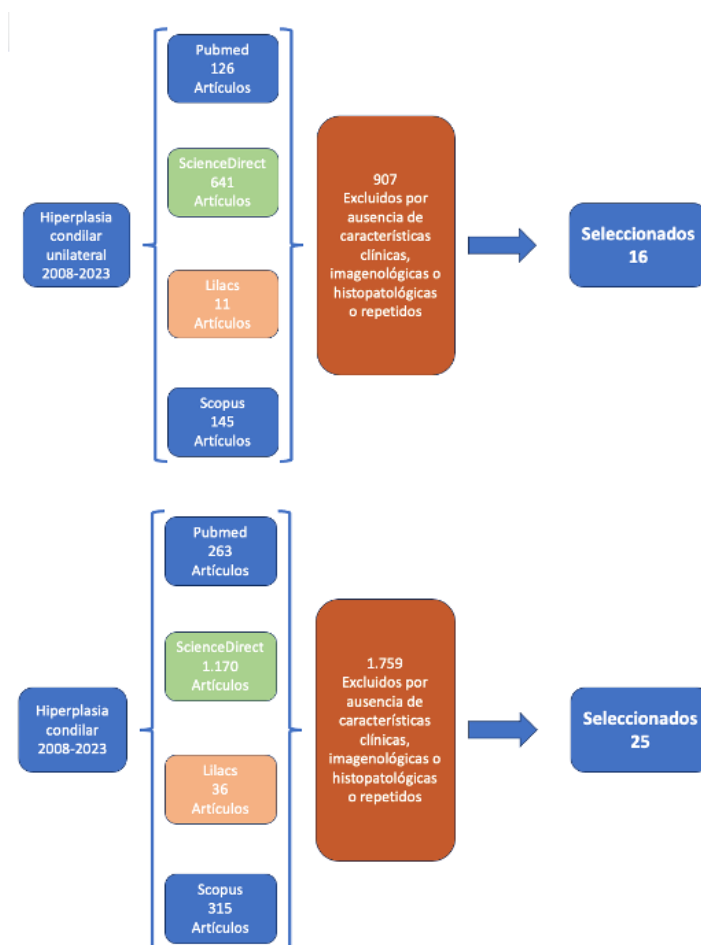


FIGURE 1  
Article selection and search scheme

Once the search and selection of articles was conducted, 41 articles corresponding to literature reviews, clinical cases and systematic reviews were selected because they contained in their structure information regarding clinical, imaging and histopathological characteristics, with an established treatment plan (1-41). On the other hand, articles were excluded for not meeting the requirements associated with the search related to the treatment and the characteristics necessary to achieve the diagnosis of condylar hyperplasia. Data collection and registration were conducted in the Excel 2022 program, in which the frequency and prevalence variables were included, in addition to including data related to the demographic variables, type of study, year of publication of these and whether they required surgical management of condylectomy or combined with orthognathic surgery.

## RESULTS

During the literature review, there were 31 systematic, bibliographic reviews and clinical studies (75.61 %), and 10 clinical cases (24.39 %).

In 35 of the reviewed articles (85.37 %) the gender of the population under study is not mentioned, nor the average age, however, in all of them stomatological alterations are mentioned such as changes in occlusion, temporomandibular dysfunction and facial asymmetry.

Of all the alterations, facial asymmetry stood out in 95.38 % of cases, categorizing it as moderate to severe, while 4.62 % mentioned changes in occlusion and temporomandibular dysfunction without facial asymmetry. The types of alterations, type of study and some of the studies are detailed in Table 1.

TABLE 1  
Stomatological alterations of condylar hyperplasia

Author	Sample (M/F)	Age/Average Age	Year	Type of study	Stomatological Alterations
Li, Y et al (13)	X	X	2022	Retrospective	Changes in occlusion and temporomandibular dysfunction
Aerden, T. et al (14)	X	X	2022	Retrospective	Changes in occlusion and temporomandibular dysfunction
Meuli, S. et al (15)	M:1	40 Years	2022	Clinical case	Changes in occlusion
Gallagher, AL. et al (16)	X	X	2021	Retrospective	Facial asymmetry and temporomandibular dysfunction
Dattani, A. et al (17)	X	X	2021	Clinical case and literature review	Facial asymmetry
Rueda, CAC. et al (18)	M:1	23 Years	2021	Clinical case	Facial asymmetry and changes in occlusion
Wang, AX (19)	X	X	2021	Literature review	Facial asymmetry, temporomandibular dysfunction and changes in occlusion
Maniskas, SL. et al (20)	X	X	2020	Systematic Review	Facial asymmetry

Source: the authors.

Regarding the proposed treatment, the surgical management of condylectomy versus combined with orthognathic surgery, it was found that in 63.64 % of the articles analyzed they were treated only with

high condylectomy and subsequent orthodontics, while 36.36 % of these were They managed with high condylectomy plus orthognathic surgery in the same surgical procedure or in a second surgical procedure, which can be listed in Table 2.

**TABLE 2**  
**Surgical management: condylectomy vs combined**

<b>Author</b>	<b>Year</b>	<b>Surgical management: Condylectomy Vs combined</b>
Maniskas, SA. et al (20)	2020	Combined
Ha, SW. et al (21)	2020	Condylectomy
Kim, JY. et al (22)	2019	Condylectomy
Nolte, JW. et al (23)	2018	Condylectomy
Usumi-Fujita, R. et al (24)	2018	Combined
Vernucci, RA. et al (25)	2018	Condylectomy
Mouallen, G. et al (26)	2017	Combined
López, DF. et al (27)	2017	Combined
López, DF. et al (28)	2016	Condylectomy
Kim, HS. et al (29)	2016	Combined
Fariña, R. et al (30)	2016	Condylectomy
Ghawsi, S. et al (31)	2016	Condylectomy
Janakiraman, N. et al (32)	2015	Combined
Olate, S. et al (33)	2015	Condylectomy
Fariña, R. et al (34)	2015	Condylectomy
Xavier, SP. et al (35)	2014	Combined
Chiarini, L. et al (36)	2014	Condylectomy
Ferreira, S. et al (37)	2014	Condylectomy
Butt, FMA. et al (38)	2011	Combined
Abboud, WA. et al (39)	2023	Condylectomy
Olate, S. et al (40)	2023	Condylectomy
Beltrán, J. et al (41)	2023	Condylectomy

## **Ethical considerations**

The established ethical protocols and the Declaration of Helsinki (42) were applied in all procedures that involved the participation of human beings in the study. Written authorization was obtained from the patients to publish their clinical photographs and disclose the cases. In addition, the guidelines established by the International Committee of Medical Journal Editors were followed, guidelines that are designed to promote scientific and ethical integrity in the publication of research results, which were structured from authorship, author responsibility, conflicts of interest. , informed consent, data management and reproducibility, to integrity in the presentation of results.

## **DESCRIPTION OF THE CASES**

### **Case 1**

16-year-old female patient, with no personal or family medical history of importance for the current condition, who attended the emergency consultation with her mother at the Regional Hospital of Rionegro, San Juan de Dios, referred by general dentistry when presenting symptoms. painful at the preauricular level of the left temporomandibular joint (TMJ), manifests with limitation in mouth opening, also reports constant neuralgia, denies previous surgical interventions associated with the case (Figure 2A, B and C and Figure 3A and B).



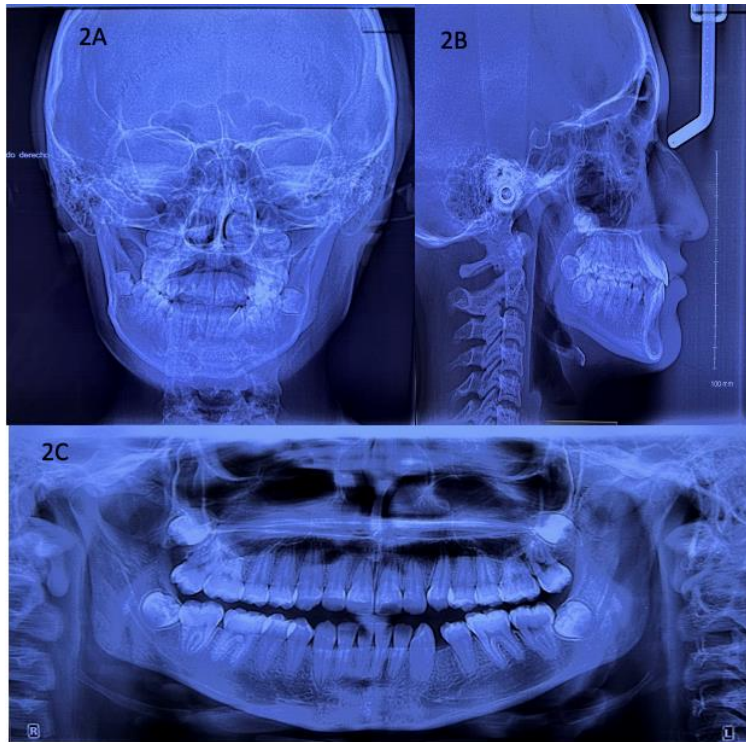


FIGURE 2

2a, b, c: initial radiographs: posteroanterior, lateral head and panoramic

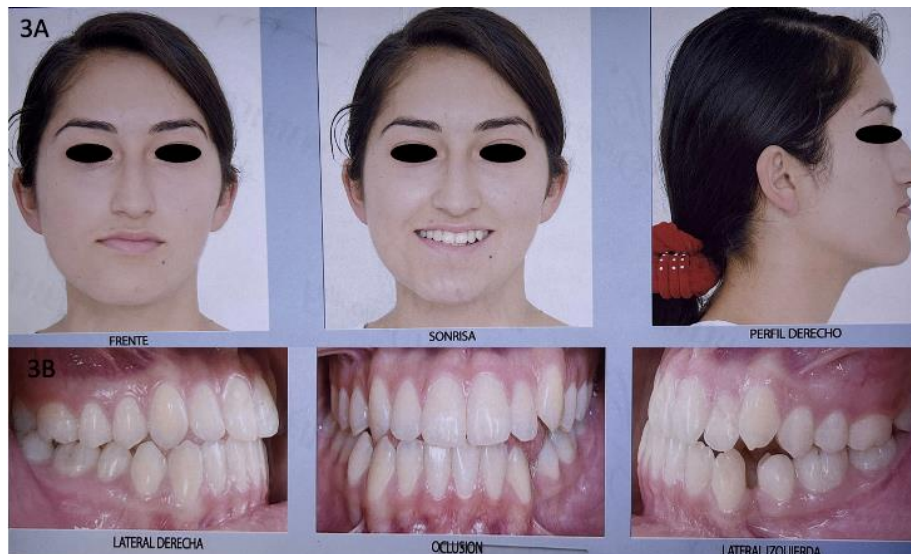

FIGURE 3

3a and b: initial photographs

In the clinical examination carried out in the maxillofacial surgery area, the patient reported evident facial asymmetry, mandibular prognathism even with orthopedic treatment during childhood, now with

progressive mandibular deviation, in 2018 she began orthodontic treatment with extraction of the tooth number 34 with the purpose of correcting the dental midline, the treatment was completed but continued with mandibular deviation and painful symptoms in the left TMJ and sporadic edema, clinically there is evidence of limitation of opening, considerable mandibular deviation to the right with chin deviated to 8 millimeters on the right, slight pain in the lateral and posterior pole of the mandibular condyles, at oroscopy even with non-active orthodontic appliances, a tendency to right posterior crossbite and left posterior scissors bite is observed, which is why a panoramic x-ray is requested and posteroanterior cephalic (PA) in which an increase in the vertical and transverse size of the mandibular ramus is observed, suggesting type III right hemi mandibular hyperplasia, in addition to left vertical and transverse predominance accompanied by deviation of the midline to the right side, which is corroborated by unevenness. of all planes in Grummons and Thilander tracing in the 10th week of orthodontic treatment (Figure 4A, B and C).

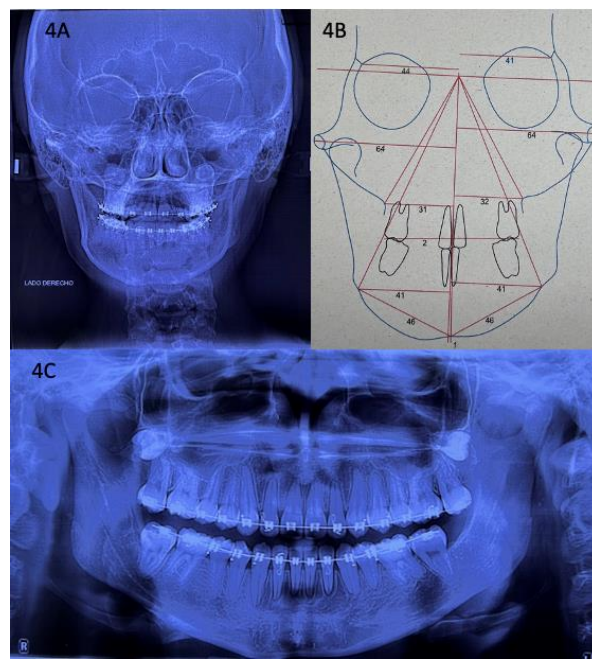


FIGURE 4

Posteroanterior and panoramic radiographs, Grummons and Thilander tracing

Due to suspicion of condylar hyperplasia, bone scintigraphy plus SPECT is requested, which shows 41 % uptake of the right condyle and 59 et catabolic hyper uptake of the left condyle, which allows establishing the differential diagnosis of active left condylar hyperplasia, which generates a large latero-prognathism on the right. . When analyzing the case, condylectomy, left meniscopexy and histopathology study, plus orthodontics, were established as the most appropriate treatment plan.

The procedure was performed under general anesthesia, with prior informed consent. Marking with methylene blue, left preauricular incision, blunt dissection up to the temporal fascia, dissection continued with a subparotid approach, dissection and approach to the condylar neck and then to the condyle in all its poles, high condylectomy with a saw that was sent to histopathology study, disc release, meniscopexy of the articular disc and placement of miniharpon micorfix quixanchor plus 4.0 Mitek, suture by capsule planes, then reconstruction of the meniscus and finally fascia, subcutaneous cellular tissue with vicryl and skin with prolene 5.0. At monthly control, improvement was evident, with no requirement for preoperative medication management, and no postoperative adverse events occurred (Figure 5A and B).



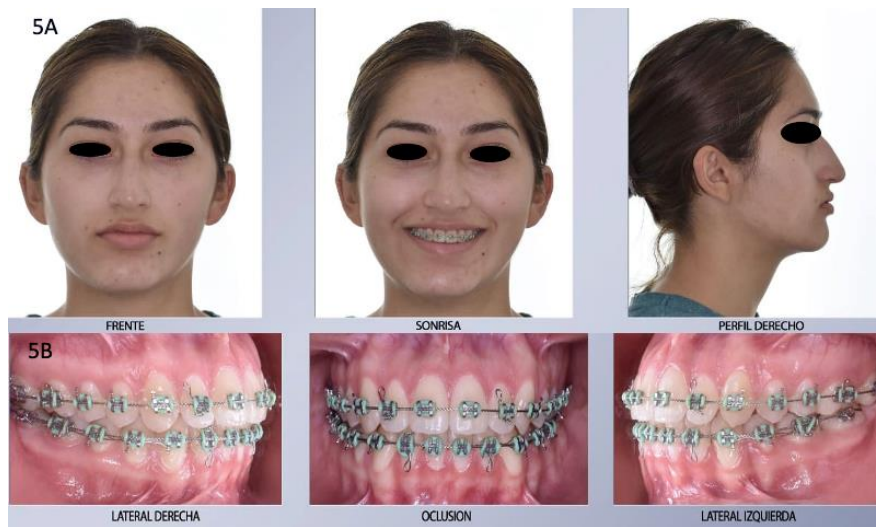


FIGURE 5

5a and b: intra and extraoral photographs with post-surgical orthodontics

In the post-surgical control one year later, there was a pleasant improvement in previously described patterns, a centered midline, stable occlusion and no evidence of recurrence or new changes associated with the pathological entity, which establishes a favorable prognosis (Figure 6A and B). During the post-surgical check-ups, the patient reports feeling comfortable and happy with her physical appearance.

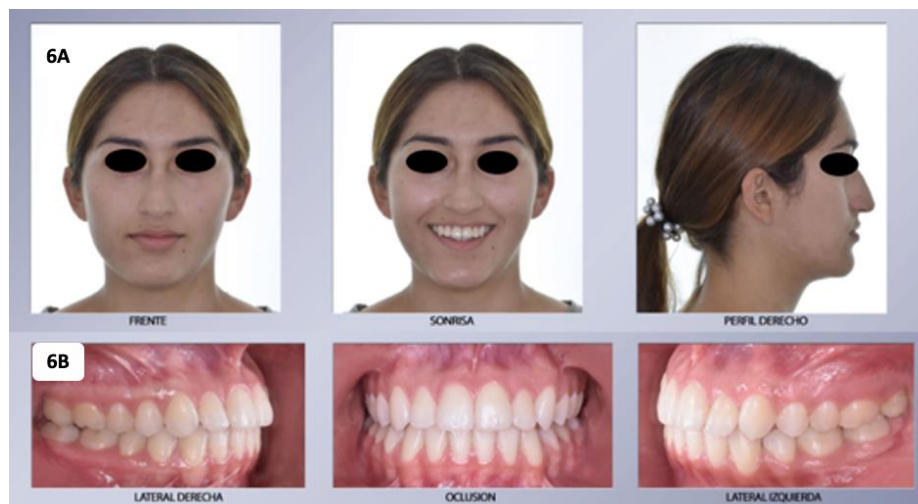


FIGURE 6

6a and b: intra and extraoral photographs with 1 year postoperative

## Case 2

A 19-year-old male patient, who comes to the private Stomatology and Maxillofacial Surgery clinic, with no significant personal, surgical or family history, reports that approximately 2 years ago he noticed changes both in his face and teeth. reason why he consulted Dentistry for the first time, where he was referred to the Maxillofacial Surgery service where the physical examination revealed a clear right hemifacial asymmetry, hypoplasia of the middle third, dentomaxillofacial anomaly (ADF) class III, left crossbite, with deviation of the lower dental midline to the left by 4 mm, for which panoramic, PA and lateral cephalic radiography is requested (Figure 7) in which the presence of right hemi mandibular hyperplasia type III is corroborated, according to the Obweser classification and Makek, for all these reasons, a treatment regimen consisting of high condylectomy and meniscopexy is proposed, which is performed under general anesthesia with prior informed consent, without the requirement for preoperative medication management, and no postoperative adverse events occur (Figure 8).

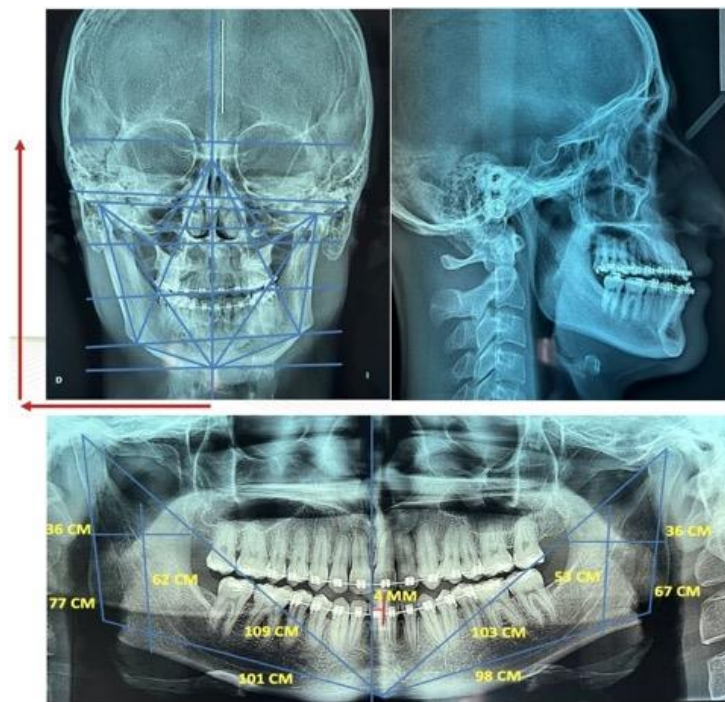


FIGURE 7

Lateral head and panoramic radiographs with measurements that demonstrate right asymmetry.

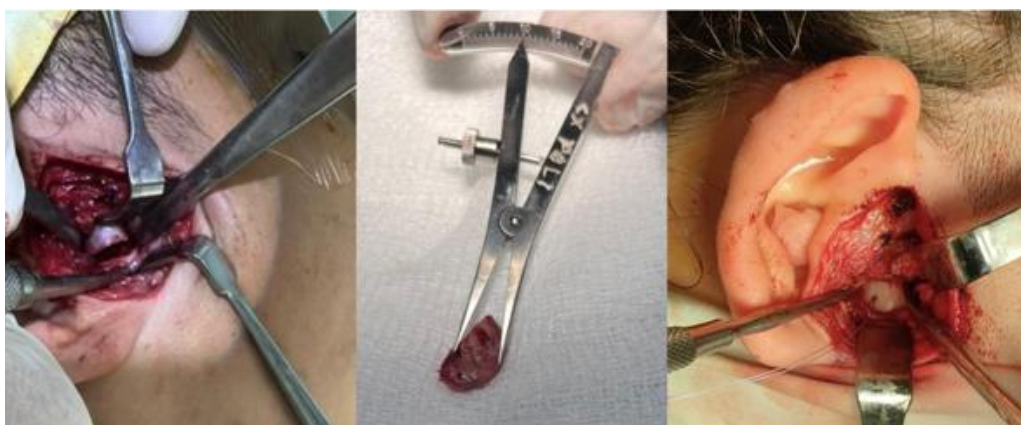

FIGURA 8

## Right upper condylectomy

In post-surgical follow-up after 2 years, there is evidence of occlusal stability and no changes at the facial level, which allows for a favorable prognosis; however, there are no control x-rays due to transfer of the patient to another city, which constitutes a limitation. of the case for timely follow-up. During the check-ups, the patient reports feeling good and indicates that it was the best thing that has happened to him.

## DISCUSSION

The main limitation of the study is determined by the heterogeneity between the studies: differences in design, populations studied and interventions; on the other hand, despite the efforts to carry out exhaustive searches in the most used databases, it is possible that some databases Relevant data or sources in other countries have not been considered, which may result in a partial view of the available evidence, as well as the inclusion only of studies in specific languages, which may limit the generalization of the results in the present study.

Primary surgery for condylar hyperplasia is based on condylectomy, which is the most effective for controlling the progression of the disease by removing the bone growth center as well as the inflammatory and proliferative tissue, which allows for better functionality. aesthetics and control of postoperative recurrences (16).

Authors such as Barajas *et al*, in 2019 presented a clinical case of a female patient who presented left unilateral condylar hyperplasia, who underwent high condylectomy and mandibular osteotomy. After the postoperative period, aesthetic improvement of facial harmony and preserved occlusion was found (41). This article shares many points in common with the case presented, the only thing that differs is the mandibular osteotomy.

Beltran J *et al* in 2023, mention in their study the performance of high condylectomies in a group of 41 women and 8 men between the ages of 10 and 45 with CH, of the 49 patients only 28.5 % received a second type of surgery. orthognathic for aesthetic reasons for the treatment of facial asymmetry (41). Likewise, in the study by Kim *et al* in 2019, a retrospective review of 27 patients with condylar hyperplasia was conducted between 2000 and 2017, among which 5 of the patients underwent condylectomy alone, 13 patients had condylectomy with orthodontics and 9 patients with complementary mandibular surgery and orthodontics, where all patients had occlusion results stable without recurrence and improvement of subjective symptoms (13). Studies differ from the present case, except in patients who had a single surgical intervention.

In 2022, Li *et al* conducted a retrospective study with 47 patients who presented active unilateral condylar hyperplasia, who underwent condylectomy and standard postoperative orthodontic treatment, which helped to improve facial asymmetry, occlusion, and locate the affected condyle. the glenoid cavity (13). Which coincides with the treatment plan of this clinical case in terms of surgical management and orthodontics.

## CONCLUSIONS

Adequate surgical planning and predetermination by the multidisciplinary team in condylar hyperplasia is fundamentally based on bone maturation, degree of severity and age of the patient, so it is worth highlighting the importance of providing clear and understandable information to the patient about the pathology. The treatment of CH is definitely surgical, with condylectomy being the procedure of choice, a treatment that can be complemented with orthognathic surgery in those cases in which it is imperative,

followed in any of the clinical situations by orthodontic management to achieve functionality and aesthetics.

## RECOMMENDATIONS

Although the review conducted supports a greater number of cases in which treatment is mainly performed with condylectomy, more studies are considered necessary that can provide either new techniques or a treatment plan in favor of the patient's well-being, as well as the collaboration and coordination of multidisciplinary teams to guarantee a comprehensive clinical evaluation and adequate patient care. It is also encouraged to conduct studies that include databases and languages that were not considered in the present study to avoid limitations in the generalization of the results.

## References

1. Arora KS, Bansal R, Mohapatra S, Pareek S. Review and Classification Update: Unilateral condylar hyperplasia. *BMJ Case Rep.* 2019 Feb 7; 12(2): e227569. <http://dx.doi.org/10.1136/bcr-2018-227569>
2. López DF, Botero JR, Muñoz JM, Cardenas-Perilla RA. Mandibular and temporomandibular morphologic characteristics of patients with suspected unilateral condylar hyperplasia: a CT study. *Dental Press J Orthod.* 2020 Mar; 25(2): 61-68. <http://dx.doi.org/10.1590/2177-6709.25.2.061-068.oar>
3. Sedano Balbin G, Pérez Vargas F, Romero Tapia P. Hiperplasia condilar, un enfoque actual del diagnóstico y tratamiento. Revisión de la literatura. *Odontol Sanmarquina.* 31 de mayo de 2019; 22(2): 132-139.
4. Yáñez-Zurita C, Bacuilima-Chimbo J. Crecimiento y Desarrollo Craneofacial: Mini-review de la Teoría de Servosistema. *Rev Med HJCA.* 2021; 13(3): 187-192. <http://dx.doi.org/10.14410/2021.13.3.rb.30>
5. Barajas-Pérez VH, Cazar-Almache ME, Miranda-Villasana JE, Recendez-Santillan NJ, Cuevas-González JC, Zambrano-Galván G. Manejo Quirúrgico de la Hiperplasia Condilar Tipo 2: Reporte de un Caso. *Int. J. Odontostomat.* 2019; 13(1): 5-10. <http://dx.doi.org/10.4067/S0718-381X2019000100005>.
6. Sofyanti E, Boel T, Satria D, Ritonga ZF, Hasibuan IH. Differences in dental arch characteristics between genders in patients with suspected condylar hyperplasia in a North Sumatra subpopulation: a cross-sectional study. *F1000Res.* 2020 Apr 16; 9:263. <http://dx.doi.org/10.12688/f1000research.22780.3>
7. Yu J, Yang T, Dai J, Wang X. Histopathological features of condylar hyperplasia and condylar Osteochondroma: a comparison study. *Orphanet J Rare Dis.* 2019 Dec 16; 14(1): 293. <http://dx.doi.org/10.1186/s13023-019-1272-5>
8. López DF, Ríos Borrás V, Muñoz JM, Cardenas-Perilla R, Almeida LE. SPECT/CT Correlation in the Diagnosis of Unilateral Condilar Hyperplasia. *Diagnostics (Basel).* 2021 Mar 8; 11(3): 477. <http://dx.doi.org/10.3390/diagnostics11030477>
9. Céspedes E, Pardo H, Bravo M. Alternatives for Treatment of Facial Asymmetry by Condylar Hyperplasia: A Review. *J Orthod Endod.* 2018; 4(3):15. <https://doi.org/10.21767/2469-2980.100049>
10. Carrasco Rueda CA, Vinitzky Brener I. Condylectomia baja intraoral para el tratamiento de hiperplasia condilar. Reporte de un caso. *Rev Esp Cirug Oral Maxilofac.* 2021; 43(3): 101-104. <https://dx.doi.org/10.20986/recom.2021.1227/2020>
11. Rojas BR, Ramírez MI, Orozco NI, Rodríguez LR, Simg AA, Quirarte VM. Alternativas diagnósticas y de tratamiento para la corrección de asimetrías faciales: Revisión bibliográfica. *Rev Cient Odontol.* 2022; 10(1): e098. <https://doi.org/10.21142/2523-2754-1001-2022-098>
12. Borges TM, Sol I, de Castro Rodrigues CM, Peres Lima FGG, Silva CJ, Furtado LM. Surgery First Approach in Orthognathic Surgery - Considerations and Clinical Case Report. *Ann Maxillofac Surg.* 2021 Jul-Dec; 11(2): 349-351. [https://doi.org/10.4103/ams.ams\\_8\\_21](https://doi.org/10.4103/ams.ams_8_21)
13. Li Y, Zheng Y, Cai H, Meng Q, Fang W, Ke J, Long X, Chen G. Standard orthodontic treatment after condylectomy for patients with active unilateral condylar hyperplasia. *Am J Orthod Dentofacial Orthop.* 2022 Mar; 161(3): 404-415. <https://doi.org/10.1016/j.ajodo.2020.09.032>
14. Aerden T, Verstraete L, Politis C. The need for secondary orthognathic surgery after high condylectomy in patients with active unilateral condylar hyperplasia. *Int J Oral Maxillofac Surg.* 2022 Feb; 51(2): 206-213. <https://doi.org/10.1016/j.ijom.2021.04.007>
15. Meuli S, Amodeo G, Marrocco S, Brugnami F, Scopelliti D. Surgery First and Clear Aligners on Relapsed Condylar Hyperplasia. *J Craniofac Surg.* 2022 Jan-Feb 01; 33(1): e60-e65. <https://doi.org/10.1097/SCS.00000000000007947>
16. Gallagher AL, Ruellas ACO, Benavides E, Soki FN, Aronovich S, Magraw CBL, Turvey T, Cevitanes L. Mandibular condylar remodeling characteristics after simultaneous condylectomy and orthognathic surgery. *Am J Orthod Dentofacial Orthop.* 2021 Nov; 160(5): 705-717. <https://doi.org/10.1016/j.ajodo.2020.06.040>



17. Dattani A, Heggie A. Hemifacial hyperplasia: a case series and review of the literature. *Int J Oral Maxillofac Surg.* 2021 Mar; 50(3): 341-348. <https://doi.org/10.1016/j.ijom.2020.05.008>
18. Carrasco Rueda CA, Vinitzky Brenner I. Condilectomía baja intraoral para el tratamiento de hiperplasia condilar. Reporte de un caso. *Rev Esp Cirug Oral y Maxilofac.* 2021 Sep; 43(3): 101-104. <https://dx.doi.org/10.20986/recom.2021.1227/2020>
19. Wang, A. Diagnosis and treatment of benign condylar hyperplasia. *Journal of Prevention and Treatment for Stomatological Diseases.* 2021; 29(6): 361-367. <https://dx.doi.org/10.12016/j.issn.2096-1456.2021.06.001>
20. Maniskas S, Ly CL, Parsaei Y, Bruckman KC, Steinbacher DM. Facial Asymmetry in Unilateral Condylar Hyperplasia: Comparing Treatment for Active versus Burnt-Out Disease. *Plast Reconstr Surg.* 2020 Oct; 146(4): 439e-445e. <https://dx.doi.org/10.1097/PRS.00000000000007154>
21. Ha SW, Choi JY, Baek SH. Correction of unilateral condylar hyperplasia and posterior open bite with proportional condylectomy and fixed orthodontic treatment. *Angle Orthod.* 2020 Jan; 90(1): 144-158. <https://dx.doi.org/10.2319/080818-585.1>
22. Kim JY, Ha TW, Park JH, Jung HD, Jung YS. Condylectomy as the treatment for active unilateral condylar hyperplasia of the mandible and severe facial asymmetry: retrospective review over 18 years. *Int J Oral Maxillofac Surg.* 2019 Dec; 48(12): 1542-1551. <https://dx.doi.org/10.1016/j.ijom.2019.06.022>
23. Nolte JW, Schreurs R, Karssemakers LHE, Tuinzing DB, Becking AG. Demographic features in Unilateral Condylar Hyperplasia: An overview of 309 asymmetric cases and presentation of an algorithm. *J Craniomaxillofac Surg.* 2018 Sep; 46(9): 1484-1492. <https://dx.doi.org/10.1016/j.jcms.2018.06.007>
24. Usumi-Fujita R, Nakakuki K, Fujita K, Kosugi M, Yonemitus I, Fukuyama E, Ono T. Collaborative treatment for a case of condylar hyperplastic facial asymmetry. *Angle Orthod.* 2018 Jul; 88(4): 503-517. <https://dx.doi.org/10.2319/081517-549.1>
25. Vernucci RA, Mazzoli V, Galluccio G, Silvestri A, Barbato E. Unilateral hemimandibular hyperactivity: Clinical features of a population of 128 patients. *J Craniomaxillofac Surg.* 2018 Jul; 46(7): 1105-1110. <https://dx.doi.org/10.1016/j.jcms.2018.04.028>
26. Mouallem G, Vernex-Boukema Z, Longis J, Perrin JP, Delaire J, Mercier JM, Corre P. Efficacy of proportional condylectomy in a treatment protocol for unilateral condylar hyperplasia: A review of 73 cases. *J Craniomaxillofac Surg.* 2017 Jul; 45(7): 1083-1093. <https://dx.doi.org/10.1016/j.jcms.2017.04.007>
27. López DF, Aristizábal JF, Martínez-Smit R. Condylectomy and "surgery first" approach: An expedited treatment for condylar hyperplasia in a patient with facial asymmetry. *Dental Press J Orthod.* 2017 Jul-Aug; 22(4): 86-96. <https://dx.doi.org/10.1590/2177-6709.22.4.086-096.oar>
28. Lopez DF, Herrera-Guardiola S. Orthodontic Treatment after High Condylectomy in Patients with Unilateral Condylar Hyperplasia. *J Clin Orthod.* 2016 Dec; 50(12): 727-735
29. Kim HS, Kim JY, Huh JK, Park KH. A surgical strategy for severe facial asymmetry due to unilateral condylar overgrowth. *Int J Oral Maxillofac Surg.* 2016 May; 45(5): 593-600. <https://dx.doi.org/10.1016/j.ijom.2015.12.007>
30. Fariña R, Olate S, Raposo A, Araya I, Alister JP, Uribe F. High condylectomy versus proportional condylectomy: is secondary orthognathic surgery necessary? *Int J Oral Maxillofac Surg.* 2016 Jan; 45(1): 72-77. <https://dx.doi.org/10.1016/j.ijom.2015.07.016>
31. Ghawsi S, Aagaard E, Thygesen TH. High condylectomy for the treatment of mandibular condylar hyperplasia: a systematic review of the literature. *Int J Oral Maxillofac Surg.* 2016 Jan; 45(1): 60-71. <https://dx.doi.org/10.1016/j.ijom.2015.09.002>
32. Janakiraman N, Feinberg M, Vishwanath M, Nalaka Jayaratne YS, Steinbacher DM, Nanda R, Uribe F. Integration of 3-dimensional surgical and orthodontic technologies with orthognathic "surgery-first" approach in the management of unilateral condylar hyperplasia. *Am J Orthod Dentofacial Orthop.* 2015 Dec; 148(6): 10541-66. <https://dx.doi.org/10.1016/j.jado.2015.08.012>
33. Olate S, Cantín M, Palmieri C, Alister JP, Muñoz M, Moraes M. Mandibular condyle repair after condylectomy in patients with condylar hyperplasia. Case series report. *Int. J. Morphol.* 2015; 33(2): 759-763, <https://doi.org/10.4067/S0717-95022015000200054>
34. Fariña R, Pintor F, Pérez J, Pantoja R, Berner D. Low condylectomy as the sole treatment for active condylar hyperplasia: facial, occlusal and skeletal changes. An observational study. *Int J Oral Maxillofac Surg.* 2015 Feb; 44(2): 217-225. <https://doi.org/10.1016/j.ijom.2014.10.013>
35. Xavier SP, Santos Tde S, Silva ER, Faria AC, de Mello Filho FV. Two-stage treatment of facial asymmetry caused by unilateral condylar hyperplasia. *Braz Dent J.* 2014; 25(3): 257-260. <https://doi.org/10.1590/0103-6440201302150>
36. Chiarini L, Albanese M, Anesi A, Galzignato PF, Mortellaro C, Nocini P, Bertossi D. Surgical treatment of unilateral condylar hyperplasia with piezosurgery. *J Craniofac Surg.* 2014 May; 25(3): 808-810. <https://doi.org/10.1097/SCS.0000000000000699>



37. Ferreira S, da Silva Fabris AL, Ferreira GR, Faverani LP, Francisconi GB, Souza FA, Garcia IR Jr. Unilateral condylar hyperplasia: a treatment strategy. J Craniofac Surg. 2014 May; 25(3): e256-8. <https://doi.org/10.1097/SCS.0000000000000554>
38. Butt FM, Guthua SW, Nganga P, Edalia M, Dimba EA. One-stage treatment of acquired facial deformity caused by severe unilateral condylar hyperplasia. J Craniofac Surg. 2011 Sep; 22(5): 1966-1968. <https://doi.org/10.1097/SCS.0b013e31822eaa8b>
39. Abboud WA, Romano R, Ledermann S, Shashua D, Naddaf R, Tulchinsky M, Kadry R, Shamir D. Can Condylectomy Alone Achieve Facial Symmetry in Patients With Hemimandibular Hyperplasia (Condylar Hyperplasia Type 2)? J Craniofac Surg. 2023 Jul-Aug 01; 34(5): 1479-1484. <https://doi.org/10.1097/SCS.00000000000009294>
40. Olate S, Ravelo V, Alister JP, Netto HD, Haidar ZS, Sacco R. Early Treatment of Unilateral Condylar Hyperplasia in Adolescents: Preliminary Results. J Clin Med. 2023 May 11; 12(10): 3408. <https://doi.org/10.3390/jcm12103408>
41. Beltran J, Zaror C, Moya MP, Netto HD, Olate S. Diagnosis and Treatment in Unilateral Condylar Hyperplasia. J Clin Med. 2023 Jan 28; 12(3): 1017. <https://doi.org/10.3390/jcm12031017>
42. Mesa-Trujillo D, Espinosa-Ferro Y, García-Mesa I. Reflexiones sobre bioética médica. Rev Med Electrón. 2022 Abr; 44(2): 413-424.

\* Original research.

***How to cite this article:*** Tovío-Martínez E, Urbano-del-Valle S, Giraldo-Rendón LL, Córdoba-Mosquera J. Evaluation of surgical management in condylar hyperplasia: from diagnosis to treatment monitoring. Univ Odontol. 2023; 42. <https://doi.org/10.11144/Javeriana.uo42.esmc>