

## Imaging Evaluation of Morphological Changes in the Temporomandibular Joint of Growing Patients Treated with Functional Appliances. Systematic Review \*

Evaluación imagenológica de los cambios morfológicos en la articulación temporomandibular de pacientes en crecimiento tratados con aparatos funcionales. Revisión sistemática

Avaliação por imagem das alterações morfológicas da articulação temporomandibular de pacientes em crescimento tratados com aparelhos funcionais. Revisão sistemática

Jordi Tomàs Aliberas <sup>a</sup>  
Universitat Internacional de Catalunya. Barcelona, España  
jtomas@uic.es  
<https://orcid.org/0000-0002-5054-2719>

DOI : <https://doi.org/10.11144/Javeriana.uo42.iemc>  
Submission Date: 21 July 2023  
Submission Date: 20 December 2023  
Publication Date: 22 December 2023

Catalina Pizarro Lavín <sup>a</sup>  
Independent practice. Chile  
ccpizarrolavin@gmail.com  
<https://orcid.org/0009-0000-9403-1147>

Dídac Sotorra Figuerola <sup>a</sup>  
Universitat Internacional de Catalunya. Barcelona, España  
sotorrad@gmail.com  
<https://orcid.org/0000-0001-5118-9913>

Natalia Felipe Spada <sup>a</sup>  
Universitat Internacional de Catalunya. Barcelona, España  
nfelipe@uic.es  
<https://orcid.org/0000-0002-7283-1386>

**Authors' Note:** <sup>a</sup> **Correspondence:** jtomas@uic.es; ccpizarrolavin@gmail.com; sotorrad@gmail.com; nfelipe@uic.es

### ABSTRACT

**Background:** A wide range of functional devices allow stimulating mandibular growth in class II patients, through mandibular advancement; managing to correct this type of skeletal and occlusal disharmony. Fixed repositioning appliances apply constant forces to the TMJ and may cause remodeling of the articular condyle and glenoid fossa. Computed tomography (CT) has been the gold standard for imaging the bone and hard tissues of the TMJ, but today cone beam computed tomography (HCCT) and Nuclear Magnetic Resonance (MRI) are used, because of their low and zero levels, respectively, of radiation. **Objective:** to measure morphological changes through TMJ imaging evaluation after correction of class II malocclusion with functional treatment with appliances in growing patients **Methods:** a comprehensive systematic literature search was conducted from January 2015 to May 2023 in the following bibliographic databases PubMed, EBSCO, Embase, and the Cochrane Library. **Results:** 10 studies were selected. The total sample size was 210 patients, and the age range was 10.3 to 14 years. The main imaging method used was HCCT with n = 9. **Conclusions:** The main change described is condylar remodeling, followed by morphological adaptation of the fossa. Although no significant differences have been reported in morphological changes in the TMJ between fixed versus removable functional appliances, fixed appliances cause a higher incidence of morphological changes.

**Keywords:** cone-beam computed tomography; dentistry; diagnostic techniques and procedures; functional appliances; nuclear magnetic resonance; orthodontic appliances; orthodontics; temporomandibular changes; temporomandibular joint

## RESUMEN

**Antecedentes:** Una amplia gama de aparatos funcionales permiten estimular el crecimiento mandibular de pacientes clase II, mediante su avance mandibular; logrando corregir este tipo de desarmonía esquelética y oclusal. Los aparatos de reposicionamiento fijos aplican fuerzas constantes sobre la ATM y pueden causar la remodelación del cóndilo articular y de la fosa glenoidea. La tomografía computarizada (TC) ha sido el estándar de oro para obtener imágenes del hueso y tejidos duros de la ATM, pero hoy en día se emplean la tomografía computarizada de haz cónico (TCHC) y la Resonancia Magnética Nuclear (RMN), a causa de sus niveles bajos y nulos respectivamente, de radiación. **Objetivo:** medir los cambios morfológicos mediante evaluación imagenológica de la ATM después de la corrección de la maloclusión de clase II con tratamiento funcional con aparatos en pacientes en crecimiento. **Métodos:** se realizó una búsqueda bibliográfica sistemática integral desde enero de 2015 hasta mayo de 2023 en las siguientes bases de datos bibliográficas PubMed, EBSCO Embase y la Biblioteca Cochrane. **Resultados:** 10 estudios fueron seleccionados. El tamaño muestral total fue de 210 pacientes, y el rango de edad fue de 10,3 a 14 años. El principal método de imagen utilizado fue la TCHC con n = 9. **Conclusiones:** El principal cambio descrito es el remodelado condilar, seguido de la adaptación morfológica de la fosa. Aunque no se han reportado diferencias significativas en los cambios morfológicos en la ATM entre aparatos funcionales fijos versus removibles, la aparatología fija causa mayor incidencia de cambios morfológicos.

**Palabras clave:** aparatología de ortodoncia; aparatología funcional; articulación temporomandibular; cambios temporomandibulares; odontología; ortodoncia; resonancia magnética nuclear; técnicas y procedimientos de diagnóstico; tomografía computarizada de haz cónico

## RESUMO

**Antecedentes:** Uma ampla gama de dispositivos funcionais permite estimular o crescimento mandibular em pacientes classe II, por meio do avanço mandibular; conseguindo corrigir esse tipo de desarmonia esquelética e oclusal. Aparelhos fixos de reposicionamento aplicam forças constantes na ATM e podem causar remodelamento do côndilo articular e da fossa glenóide. A tomografia computadorizada (TC) tem sido o padrão-ouro para a obtenção de imagens dos tecidos ósseos e duros da ATM, mas hoje são utilizadas a tomografia computadorizada de feixe cônico (TCHC) e a ressonância magnética nuclear (RM), devido aos seus níveis baixo e zero, respectivamente, de radiação. **Objetivo:** medir as alterações morfológicas por meio da avaliação por imagem da ATM após correção da má oclusão de classe II com tratamento funcional com aparelhos em pacientes em crescimento. **Métodos:** uma pesquisa bibliográfica abrangente e sistemática foi realizada de janeiro de 2015 a maio de 2023 nas seguintes bases de dados bibliográficas Pubmed, Ebsco Embase e the Biblioteca Cochrane. **Resultados:** foram selecionados 10 estudos. O tamanho total da amostra foi de 210 pacientes e a faixa etária foi de 10,3 a 14 anos. O principal método de imagem utilizado foi o TCH com n = 9. **Conclusões:** A principal alteração descrita é o remodelamento condilar, seguido de adaptação morfológica da fossa. Embora não tenham sido relatadas diferenças significativas nas alterações morfológicas da ATM entre aparelhos funcionais fixos e removíveis, os aparelhos fixos causam maior incidência de alterações morfológicas.

**Palavras-chave:** alterações temporomandibulares; aparelhos funcionais; aparelhos ortodônticos; articulação temporomandibular; odontologia; ortodontia; ressonância magnética nuclear; técnicas e procedimentos de diagnóstico; tomografia computadorizada de feixe cônico

## INTRODUCTION

Class II malocclusion is one of the most common dental and skeletal problems and occurs in approximately one third of the population (1). It is characterized by an alteration in the relationship between maxillary and mandibular bone growth and is the most common cause of mandibular retrognathia (2). Patients with class II malocclusion have some characteristics that make them more susceptible to pathologies of the temporomandibular joint (TMJ), so it is advisable to diagnose this problem at an early age to avoid future damage (3).

The main management in growing patients consists of taking advantage of the patient's growth potential and stimulating, if possible, the anterior growth of the mandible to correct Class II (2). Therefore, there is a wide range of functional appliances designed to stimulate mandibular growth through its advancement, thereby correcting this type of skeletal and occlusal disharmony (1). On average, this treatment usually lasts between 6 to 9 months. It should be considered that when the

functional apparatus (FA) is inserted, the condyles move towards an anterior position with respect to the articular eminence, being able to adapt (4).

In turn, if there is early modification of the occlusion, it is possible to prevent more severe discrepancies from developing, achieving greater help in oral health by allowing adequate development of normal chewing and facial habits (5).

It has been suggested that fixed repositioning appliances apply nearly constant forces to the TMJ and may cause remodeling of the articular condyle and glenoid fossa, repositioning of the condyle, and rotation of the mandibular body which may cause permanent damage to the structure of the TMJ. TMJ (6). Likewise, anterior repositioning and downward/forward displacement of the condyles could modify the position of the articular disc (7).

Many methods have been used in the literature to evaluate TMJ tissues. One of them, magnetic resonance imaging (MRI), is a sensitive and valid tool to analyze the morphology of the TMJ articular disc, joint effusions and the presence of synovitis, although it has limited value when it comes to accurately representing precision the bone anomalies of the TMJ (7).

Computed tomography (CT) has been the gold standard for imaging bone and hard tissues. But nowadays cone beam computed tomography (HCCT) has much lower radiation exposure than CT, being widely used in orthodontic practice for the evaluation of bone remodeling of the TMJ (6).

Given that there are different types of functional appliances for the treatment of type II malocclusions, it was decided to conduct a systematic review to evaluate the current state of how the appliances affect the TMJ. For its evaluation, it was decided to take all studies evaluated by MRI, HCCT and CT.

This review aimed to measure morphological changes through 3D imaging evaluation (HCCT and MRI) of the TMJ after correction of class II malocclusion with functional treatment with appliances in growing patients.

## **MATERIALS AND METHODS**

This systematic review was conducted following the Preferred Reporting Items for Systematic Reviews and Meta-Analyses (PRISMA) statement and the Patient, Intervention, Comparison and Outcomes (PICO) approach as appropriate in relation to the topic of the review. .

The aim is to analyze the morphological changes through the use of radiological images of the temporomandibular joint after the correction of skeletal or dental class II malocclusion with functional treatment with appliances in growing patients.

To identify all relevant publications, a comprehensive systematic literature search was conducted from January 2015 to May 2023 in the following bibliographic databases PubMed, Absco Embase and the Cochrane Library.

The key words used for the literature search were orthodontic appliances; functional appliances; temporomandibular joint; temporomandibular changes; cone beam computed tomography; nuclear magnetic resonance. The Boolean operators used to combine the keywords mentioned above were “AND” - “OR”, creating different search categories.

Inclusion criteria were determined as all clinical trials, cohort studies, case-control studies, cross-sectional studies, systematic reviews, prospective and retrospective studies that investigated the radiographic morphological changes of the TMJ after the correction of class II malocclusion with Functional treatment with appliances in growing patients. It was decided to include all studies published in English as the only language.

Inclusion was restricted to children and adolescents (up to 19 years of age in both boys and girls) who had a skeletal class II malocclusion and were treated with a fixed anterior mandibular repositioning appliance.

Any morphological change of the TMJ joint tissues, analyzed using 3D imaging modalities (MRI, CT, HCCT), was included as evaluation measures. Systematic reviews, meta-analyses, case series/reports, comments, editorials and letters were excluded. Any published study that was not written in English was excluded, as well as any study analyzed using 2D radiography (orthopantomography, cephalometry, lateral tomography).

The collected publications were imported into reference management software (EndNote X9; Thomson Reuter) and duplicate articles were excluded.

## RESULTS

After obtaining the results of the electronic and systematic search on different databases, a total of 237 articles were selected (PubMed: 148, Cochrane Library: 74, Embase: 15) considering duplicates

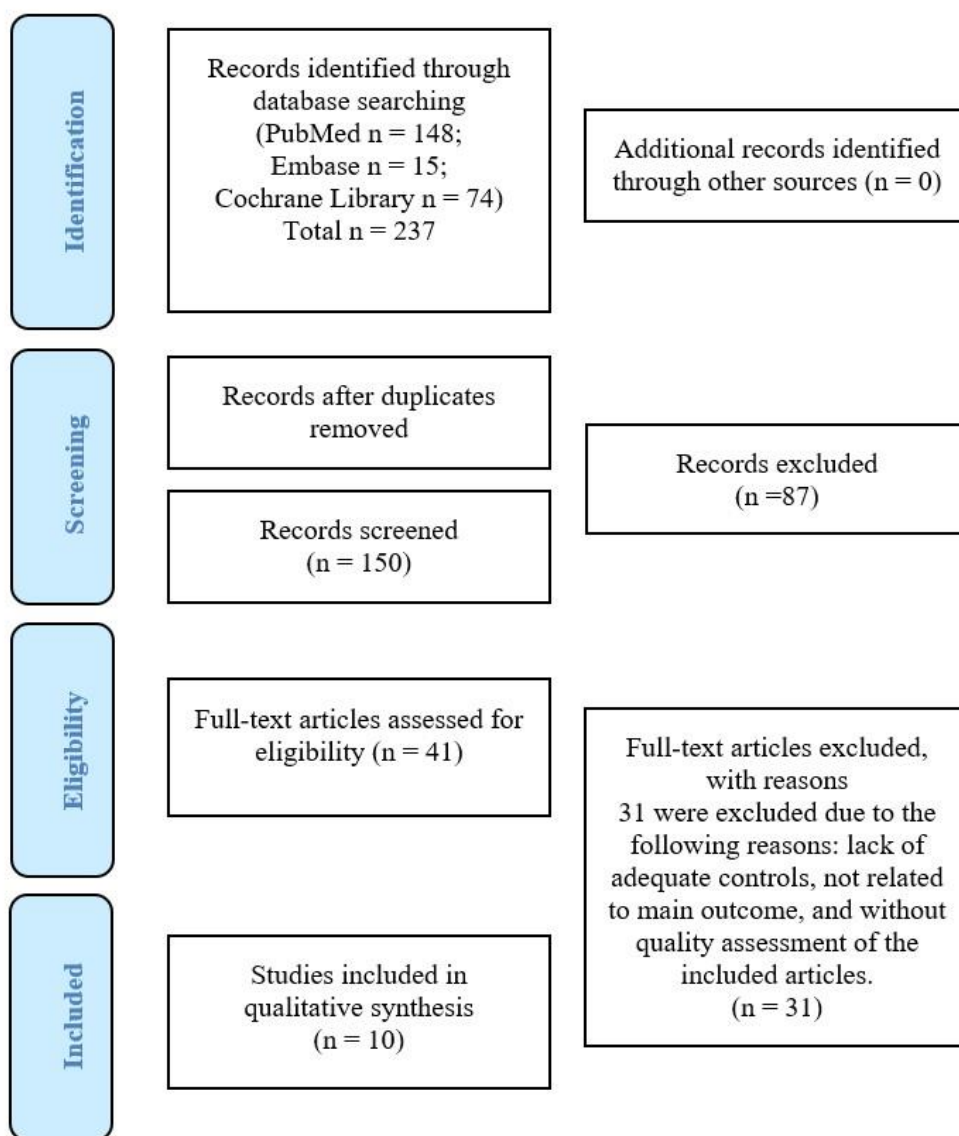


FIGURE 1

Flow chart of literature search results and process of exclusion. PRISMA flow diagram

There was no disagreement between the two investigators (CPL and JTA) during the selection and analysis of the studies.

Of the 10 studies selected, they were all observational studies, 6 were retrospective and 4 were prospective (see Table 1). The total sample of the observational studies was 210 patients, and the age range was 10.3 to 14 years.

Of all the included studies, 4 reported on Herbst (the most reported in the literature), 4 on Twin block, 2 on Forsus, 1 on Bionator and 1 on Power Scope. The main imaging method used was HCCT (considered the gold standard in the literature) with 9 studies followed by MRI only used once.

After analyzing each of the studies, it was determined that the main morphological changes were related to the condyle and then to the fossa. Therefore, the main working hypothesis and the respective specific hypotheses were accepted. The only rejected hypothesis turned out to be the one that determined greater changes in the TMJ after a class II malocclusion with fixed functional appliances compared to removable functional appliances

TABLE 1  
Selection of included studies

Study	Sample size	Study design	Functional Device	Diagnosis Image	Conclusions
Watted 2015 (8)	n = 29	Prospective	Bionator	MRI	Changes in the position of the disc, fossa and condyle after the use of Bionator
Souki 2017 (9)	n = 25	Retrospective	Herbst	CBCT	Changes in the dimension and magnitude of the condyle
Elfeky 2018 (10)	n = 22	Prospective	Twin Block	CBCT	Changes in the dimensions of the condyle in the 3D
Gandedkar 2019 (11)	n = 16	Prospective	Forsus	CBCT	Non-significant changes in the position of the condyle
Jiang 2020 (12)	n = 17	Retrospective	Twin Block	CBCT	Modifications in the glenoid fossa and position of the condyle
Wei 2016 (13)	n = 20	Prospective	Herbst	CBCT	Increased condylar growth in two-phase treatment
Fan 2020 (14)	n = 20	Prospective	Herbst	CBCT	Additional increase in condyle length in the middle of the sample
Nindra 2021 (15)	n = 20	Retrospective	Herbst	CBCT	Deposit on the posterior wall of the glenoid fossa, without changes in the position of the condyle
Pavorthy 2021 (16)	n = 26	Retrospective	Herbst, Power Scope, Forsus	CBCT	The 3 devices caused structural changes in the TMJ
Shetty 2021 (17)	n = 15	Prospective	Twin Block	CBCT	An increase in the height of the mandibular ramus and body was observed. Stimulating growth of the condyle and increasing the gonial angle

Source: the authors.

## DISCUSSION

In the present study, it was decided to use the PRISMA Declaration since it made it easier for us to analyze the effectiveness and safety of one treatment in relation to another with a high level of quality and scientific rigor in order to contribute to decision-making in the health care.

It was decided to select all studies that included imaging evaluation using 3D analysis, discarding any study that used 2D (orthopantomography, cephalometry, lateral tomography). Since TCHC is considered the gold parameter in the literature when analyzing changes in the structures that make up the TMJ.

The analysis of articles showed that scientific evidence cannot be established on the reaction of the tissues that make up TMJ, when forces are applied by anterior mandibular repositioning appliances.

Most of the included studies demonstrated, through the use of HCCT and MRI, that there was displacement of the articular disc during treatment, but most of them returned to their normal position later (8,9).

The selected studies showed that the most evaluated appliances were with 4 studies with Herbst and Twin Block respectively, and more residually Forsus (2 studies), Power Scope and Bionator with 1 study.

If each of the different devices is analyzed, it can be determined that authors such as Souki et al., in their retrospective study with a sample size of 25 patients evaluated with TCHC, established that there are three-dimensional changes in the direction and magnitude of the condyle after Herbst Therapy (9).

Regarding the removable appliance, such as Bionator, authors such as Watted et al. determined that the MRI image showed no pathological changes of the joint after treatment with Bionator, obtaining a physiological and stable shape of the fossa and condyles (8). On the other hand, authors such as Elfeky et al. determined that the changes that occurred were significant at the skeletal, dentoalveolar and condylar levels in the dimension and position of the TMJ after the use of Twin-block (10).

Shetty et al. observed modifications in the condyle-fossa relationship with an increase in height, length and width (17). Other authors, such as Gandedkar et al. studied the effect of Forsus on TMJ and revealed that there were no significant changes in TMJ after the use of this functional device (11).

Similarly, Jiang et al. concluded that there is a change in the length of the condyle with the use of Twin Block, although the changes were not significant (12).

Wei et al. and Fan et al. studied the effect of Herbst appliances on the TMJ, determining that condylar growth occurs after treatment (13,14).

Furthermore, Nindra et al. established that there are remodeling changes in the condyle and also an adaptation of the morphology of the glenoid fossa after treatment with Herbst (15).

On the contrary, Pavarthy et al., through a retrospective study, evaluated the effect of Twin-block, PowerScope and Forsus, observing that the three devices lead to changes in TMJ (16). Subjects treated with PowerScope and Forsus presented an increase in the height and width of the condyle with a decrease in the anterior and superior joint space (17).

When comparing the effect of fixed functional appliances such as Herbst, Forsus or PowerScope and removable functional appliances such as Twin block or Bionator, the literature does not mention statistically significant differences in morphological changes between them (7,9,11).

The only authors who mentioned the presence of a morphological change were Parvarthy et al. (16). They determined that the changes that occurred were in condylar height (it was reduced with the use of Twin Block) and with the use of fixed appliances, condylar height and width increased. It was found that the change in adaptive remodeling depends on time since if the changes are too rapid, degenerative remodeling may occur instead (16).

The limitations of this systematic review were based on the lack of scientific evidence collected on changes in TMJ after the use of braces, despite the exhaustive and systematic search of articles carried out. It can be suggested that the lack of scientific evidence is due to the lack of randomized clinical studies with a larger sample size. In turn, it was only decided to take 8 years as the bibliographic search

interval, from 2015 to the present; to obtain an updated sample evaluated with the new radiological tools. It was decided to only include articles published in English, to have a coherent final selection and to make it easy for the evaluators to select each of the articles included in the study.

## CONCLUSIONS

It can be concluded that there are morphological changes in the TMJ after the correction of class II malocclusion with a functional appliance. The main change described is condylar remodeling, followed by morphological adaptation of the fossa. Although no important differences have been reported in morphological changes in the TMJ between fixed functional appliances versus removable functional appliances.

No specific pathological changes in the TMJ were described in the literature after treatment with functional appliances. The relevance of these changes to TMJ remains unclear. However, it is important for clinicians to be aware of these changes for future considerations.

## References

1. Cozza P, Baccetti T, Franchi L, De Toffol L, McNamara JA Jr. Mandibular changes produced by functional appliances in Class II malocclusion: a systematic review. *Am J Orthod Dentofacial Orthop.* 2006 May; 129(5): 599.e1-12; discussion e1-6. <https://dx.doi.org/10.1016/j.ajodo.2005.11.010>
2. Atresh A, Cevidanes LHS, Yatabe M, Muniz L, Nguyen T, Larson B, Manton DJ, Schneider PM. Three-dimensional treatment outcomes in Class II patients with different vertical facial patterns treated with the Herbst appliance. *Am J Orthod Dentofacial Orthop.* 2018 Aug; 154(2): 238-248.e1. <https://dx.doi.org/10.1016/j.ajodo.2017.11.037>
3. González FK, Lazo AY, LLanes RM. Syndrome type II division 2 malocclusions and temporomandibular dysfunction. *Invest Medicoquir.* 2020; 12(1): 1-18.
4. Kinzinger GSM, Lisson JA, Booth D, Hourfar J. Are morphologic and topographic alterations of the mandibular fossa after fixed functional treatment detectable on tomograms? Visual classification and morphometric analysis. *J Orofac Orthop.* 2018 Nov; 79(6): 427-439. English. <https://dx.doi.org/10.1007/s00056-018-0156-y>
5. Bhat Zeeshan I, Naik C, Rahalkar J. Early Intervention in Skeletal Class II and dental Class II division I malocclusion. *APOS Trends in Orthodontics.* 2013; 3: 121. <https://dx.doi.org/10.4103/2321-1407.117380>
6. Nishanth B, Gopinath A, Ahmed S, Patil N, Srinivas K, Chaitanya ASK. Cephalometric and computed tomography evaluation of dentoalveolar/soft-tissue change and alteration in condyle-glenoid fossa relationship using the PowerScope: A new fixed functional appliance for Class II correction –A clinical study. *Int J Orthod Rehabil.* 2017; 8(2): 41. [https://dx.doi.org/10.4103/ijor.ijor\\_5\\_17](https://dx.doi.org/10.4103/ijor.ijor_5_17)
7. Kyburz KS, Eliades T, Papageorgiou SN. What effect does functional appliance treatment have on the temporomandibular joint? A systematic review with meta-analysis. *Prog Orthod.* 2019 Aug 12; 20(1): 32. <https://dx.doi.org/10.1186/s40510-019-0286-9>
8. Watted N, Witt E, Kenn W. The temporomandibular joint and the disc-condyle relationship after functional orthopaedic treatment: a magnetic resonance imaging study. *Eur J Orthod.* 2001 Dec; 23(6): 683-693. <https://dx.doi.org/10.1093/ejo/23.6.683>
9. Souki BQ, Vilefort PLC, Oliveira DD, Andrade I Jr, Ruellas AC, Yatabe MS, Nguyen T, Franchi L, McNamara JA Jr, Cevidanes LHS. Three-dimensional skeletal mandibular changes associated with Herbst appliance treatment. *Orthod Craniofac Res.* 2017 May; 20(2): 111-118. <https://dx.doi.org/10.1111/ocr.12154>
10. Elfeky HY, Fayed MS, Alhammadi MS, Soliman SAZ, El Boghdadi DM. Three-dimensional skeletal, dentoalveolar and temporomandibular joint changes produced by Twin Block functional appliance. *J Orofac Orthop.* 2018 Jul; 79(4): 245-258. English. <https://dx.doi.org/10.1007/s00056-018-0137-1>
11. Gandedkar NH, Shrikantaiah S, Patil AK, Baseer MA, Chng CK, Ganeshkar SV, Kambalyal P. Influence of conventional and skeletal anchorage system supported fixed functional appliance on maxillo-mandibular complex and temporomandibular joint: A preliminary comparative cone beam computed tomography study. *Int Orthod.* 2019 Jun; 17(2): 256-268. <https://dx.doi.org/10.1016/j.ortho.2019.03.008>
12. Jiang YY, Sun L, Wang H, Zhao CY, Zhang WB. Three-dimensional cone beam computed tomography analysis of temporomandibular joint response to the Twin-block functional appliance. *Korean J Orthod.* 2020 Mar; 50(2): 86-97. <https://dx.doi.org/10.4041/kjod.2020.50.2.86>

13. Wei RY, Atresh A, Ruellas A, Cevidanes LHS, Nguyen T, Larson BE, Mangum JE, Manton DJ, Schneider PM. Three-dimensional condylar changes from Herbst appliance and multibracket treatment: A comparison with matched Class II elastics. *Am J Orthod Dentofacial Orthop.* 2020 Oct; 158(4): 505-517.e6. <https://dx.doi.org/10.1016/j.ajodo.2019.09.011>
14. Fan Y, Schneider P, Matthews H, Roberts WE, Xu T, Wei R, Claes P, Clement J, Kilpatrick N, Penington A. 3D assessment of mandibular skeletal effects produced by the Herbst appliance. *BMC Oral Health.* 2020 Apr 16; 20(1): 117. <https://dx.doi.org/10.1186/s12903-020-01108-4>
15. Nindra J, Sidhu MS, Kochhar AS, Dabas A, Valletta R, Rongo R, Spagnuolo G. Three-Dimensional Evaluation of Condyle-Glenoid Fossa Complex Following Treatment with Herbst Appliance. *J Clin Med.* 2021 Oct 15; 10(20): 4730. <https://dx.doi.org/10.3390/jcm10204730>
16. Parvathy RM, Shetty S, Katheesa P. Evaluation of changes seen in TMJ after mandibular advancement in treatment of Class II malocclusions, with functional appliances, a CBCT study. *Biomed (Trivandrum).* 2021; 41(2): 236-242. <https://doi.org/10.51248/v41i2.789>
17. Shetty V, Shetty K. Evaluation of skeletal changes in mandibular ramus height, corpus length, and mandibular angle changes following twin block appliance therapy using cone-beam computed tomography: A clinical prospective study. *Int J Orthod Rehabil.* 2021; 12(3): 115. [https://doi.org/10.4103/ijor.ijor\\_3\\_21](https://doi.org/10.4103/ijor.ijor_3_21)

\* Original research.

***How to cite this article:*** Tomàs Aliberas J, Pizarro Lavin P, Sotorra Figuerola D, Felipe Spada N. Imaging evaluation of morphological changes in the temporomandibular joint of growing patients treated with functional appliances. Systematic review. *Univ Odontol.* 2023; 42. <https://doi.org/10.11144/Javeriana.uo42.iemc>